



ASA CLINICAL STATEMENT | GUIDELINE FOR ULTRASOUND DIAGNOSIS OF EARLY PREGNANCY LOSS

Endorsements

This guideline outlines the endorsed practice in the determination of pregnancy loss when there is a pregnancy of unknown viability. Recommendations can be found in the clinical guidelines of the American College of Obstetrics and Gynaecology². They are also recommended in clinical guidelines used by the Royal College Obstetricians and Gynaecologists (RCOG)³ and the New Zealand Ministry of Health New Zealand Obstetric Ultrasound Guidelines^{8,9}.

Statement

This ASA guideline outlines the endorsed practice in the determination of pregnancy loss when there is a pregnancy of unknown viability.

Definitions

Embryo: developing organism from the fourth day after fertilisation to the end of the eighth week¹⁰.

PUL: pregnancy of unknown location- positive β HCG with no intra – or extra uterine pregnancy identified.

Pregnancy loss: spontaneous loss of pregnancy before the 20 weeks gestation.

Background

Early pregnancy loss or a nonviable, intrauterine pregnancy with either an empty gestational sac or a gestational sac containing an embryo or fetus without fetal heart activity is the most common complication of early pregnancy¹¹. Identifying which ultrasound parameters are the most reliable to predict a pregnancy loss are important for a correct diagnosis.

Key Points

For these measurements and conclusions to be valid, the scan must be performed by transvaginal scan technique.

Criteria for diagnosis of pregnancy loss: (for steps to diagnosis see Figure 1)

1. An intrauterine gestational sac, without yolk sac or embryo, and mean gestational sac diameter ≥ 25 mm.
2. An intrauterine gestational sac containing an embryo with crown-rump length ≥ 7 mm, but no visible cardiac activity.
3. Follow-up ultrasound ≥ 14 days, when an intrauterine gestational sac demonstrated without yolk sac and absence of embryo with a heartbeat.
4. Follow-up ultrasound ≥ 11 days when an intrauterine gestational sac with yolk sac is demonstrated, absence of embryo with a heartbeat.

Findings suspicious of pregnancy loss requiring follow-up*

1. An intrauterine gestational sac, without yolk sac or embryo, and mean gestational sac diameter < 25 mm.
2. An intrauterine gestational sac containing an embryo with crown-rump length < 7 mm with no visible cardiac activity.
3. Follow-up ultrasound < 14 days, when an intrauterine gestational sac demonstrated without yolk sac and absence of embryo with a heartbeat.
4. Follow-up ultrasound < 11 days when an intrauterine gestational sac with yolk sac is demonstrated, absence of embryo with a heartbeat.

5. Absence of embryo ≥ 6 weeks from last menstrual period.
6. Yolk sac but empty amnion.
7. Enlarged yolk sac (>7 mm).
8. Small gestational sac in relation to the embryo size.

*Follow-up is another ultrasound performed ≥ 11 days when an embryo is present and ≥ 14 days when only a gestational sac is present.

Criteria when unable to confirm pregnancy location

If there is a positive β HCG, and no intra- or extrauterine pregnancy identified, it is appropriate to follow the diagnostic path for a Pregnancy of Unknown Location (PUL). This occurrence requires timely contact with, and ongoing review by the referring doctor or obstetric specialist. A PUL pathway should be followed with additional follow-up scans as required.

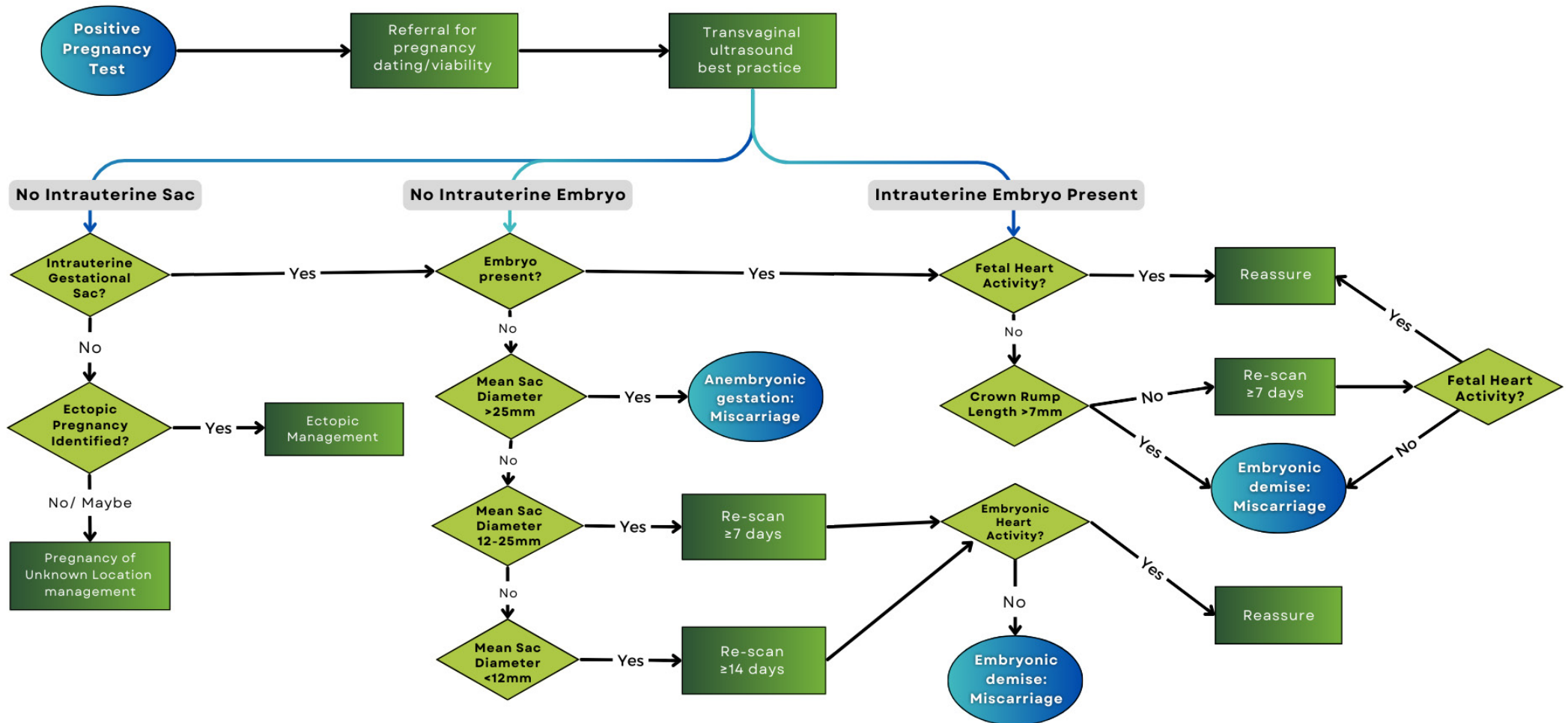
Discussion

- If there is no visible heartbeat but there is a visible embryo, measure the crown-rump length. If the embryo is not visible the mean gestational sac diameter should be measured as an estimate of gestational age³.
- Documentation of the absence of a heartbeat should be in the form of M-Mode or via Doppler techniques (including colour and spectral Doppler) to confirm pregnancy failure⁴.
- If a transvaginal ultrasound is unacceptable to the patient, an offer of a transabdominal ultrasound scan would be appropriate. The limitations of a transabdominal approach in isolation should be explained³.
- The above criteria for pregnancy loss may not be sufficiently reliable when derived from a transabdominal ultrasound. Patient refusal of a transvaginal examination should be documented, and the limitations of a transabdominal ultrasound must be made clear on the worksheet and to the reporting physician^{1,6}.
- Transabdominal imaging without transvaginal scanning may be sufficient for diagnosing early pregnancy failure when an intrauterine gestational sac contains an embryo with crown-rump length ≥ 15 mm and no visible cardiac activity¹.
- In the case of positive β HCG and a poorly formed or absent intrauterine gestational sac, a review of the female reproductive organs should include ovaries and adnexa, by transvaginal scan (when acceptable to the patient) should be performed to exclude ectopic pregnancy. The ASA endorses the RCOG criteria for ultrasound diagnosis of ectopic pregnancy⁵. The diagnostic protocol for Pregnancy of Unknown Location (PUL) should be followed in this case of positive β HCG, but no located gestational sac.
- In occasions of PUL, appropriate contact with the referring medical practitioner is recommended, including ongoing clinical review and when appropriate, a follow-up ultrasound at 7–13 days to assess for ongoing pregnancy^{2,3}.
- If a repeat scan is performed, clinical data such as current and sequential quantitative β HCG should be noted on the worksheet.
- In accordance with the ASA's Sonographer Code of Conduct⁷, sonographers should follow workplace policies and protocols when giving verbal results directly to patients. Any findings should not include a discussion of management options.

*Some authors/ international guidelines recommend a repeat scan in as brief a period as 7 days. As the trend to present earlier in pregnancy, in some cases as early as the 4th week post last menstrual period, failure to confirm a normal ongoing pregnancy at the second scan must be carefully assessed. In these cases, a diagnosis based on "failure to progress" must be made with extreme caution.

Recommendations

Figure 1. Criteria for ultrasound monitoring of first trimester pregnancy and early pregnancy loss diagnosis. ^{6, 12, 13}



References

1. Doubilet PM, Benson CB, Bourne T, Blaivas M. Diagnostic Criteria for Nonviable Pregnancy Early in the First Trimester. *N Engl J Med.* 2013;369(15):1443–51. DOI: 10.1056/NEJMr1302417
2. American College of Obstetricians and Gynecologists' Committee on Practice Bulletins—Gynecology. ACOG Practice Bulletin No. 200: Early Pregnancy Loss. *Obstet Gynecol.* 2018;132(5): e197-e207. doi:10.1097/AOG.0000000000002899
3. National Institute for Health and Care Excellence. Clinical Guideline (N126). Ectopic pregnancy and miscarriage: diagnosis and initial management. 2023. Available from <https://www.nice.org.uk/guidance/ng126/resources/ectopicpregnancy-and-miscarriage-diagnosis-and-initial-managemen-t-pdf-66141662244037>
4. Salomon LJ, Alfirevic Z, Bilardo CM, Chalouhi GE, Ghi T, KaganKO, Lau TK, Papageorghiou AT, Raine-Fenning NJ, Stirnemann J, Suresh S, Tabor A, Timor-Tritsch IE, ToiA, Yeo G. ISUOG Practice Guidelines: performance of first trimester fetal ultrasound scan. *Ultrasound Obstet Gynecol* 2013; 41: 102–113 DOI: 10.1002/uog.12342
5. Elson CJ, Salim R, Potdar N, Chetty M, Ross JA, Kirk EJ on behalf of the Royal College of Obstetricians and Gynaecologists. Diagnosis and Management of Ectopic Pregnancy. *Br J Obstet Gynaecol.* 2016;41. DOI: 10.1111/1471-0528.14189.
6. Preisler J, Kopeika J, Ismail L, Vathanan V, Farren J, Abdallah Y, et al. Defining safe criteria to diagnose miscarriage: prospective observational multicentre study. *BMJ.* 2015;351:h4579. DOI: <http://dx.doi.org/10.1136/bmj.h4579>
7. Australasian Sonographers Association. ASA Sonographer Code of Conduct. Melbourne: Australasian Sonographers Association. 2022. https://www.sonographers.org/publicassets/4f8cda47-6ad2-ec11-910e-0050568796d8/ASA_Sonographer_Code_of_Conduct_MAY_22_FINAL-v1.pdf
8. Ministry of Health. New Zealand Obstetric Ultrasound Guidelines: Early pregnancy loss. New Zealand Government. Last accessed April 2021: <https://www.health.govt.nz/our-work/life-stages/maternity-services/new-zealand-obstetricultrasound-guidelines/first-trimester/early-pregnancy-loss>
9. Ministry of Health. New Zealand Obstetric Ultrasound Guidelines: Ectopic pregnancy and pregnancy of unknown location. New Zealand G accessed April 2021: <https://www.health.govt.nz/our-work/life-stages/maternity-services/new-zealand-obstetric-ultrasound-guidelines/first-trimester/ectopic-pr-nknown-location>
10. "Embryo." Collins Dictionary of Medicine. 2004, 2005. Robert M. Youngson 19 Dec. 2021 <https://medical-dictionary.thefreedictionary.com/Embryo>
11. Detti, L., Francillon, L., Christiansen, M.E. et al. Early pregnancy ultrasound measurements and prediction of first trimester pregnancy loss: A logistic model. *Sci Rep* 10, 1545 (2020). <https://doi.org/10.1038/s41598-020-58114-3>
12. Mizia, K., Campbell Westerway, S., Robertson, M., Parry, E., Paoletti, David Perry, D., Ramkrishna, J., Macpherson, L., and George Condous, G. (2018). Guidelines for the performance of the first trimester ultrasound, *AJUM*, 21: 179-182, doi.org/10.1002/ajum.12102
13. Queensland Clinical Guidelines. Early pregnancy loss. Guideline No. MN22.29-V6-R27 Queensland Health. 2022. Available from: <http://www.health.qld.gov.au/qcg>

Acknowledgements

Sonographer Policy & Advisory Committee (SPAC)

Document Governance

- a. **Executive sponsor/Endorsed by:** ASA Board of Directors
- b. **Date of endorsement:** 2016, Feb 2022
- c. **Area responsible:** SPAC and Women's Health SIG
- d. **Consumer review:** no
- e. **Version:** v3
- f. **Date of review:** 2025

Disclaimer: The information in this publication is general in nature and does not constitute professional advice. Neither the author nor ASA (including its officers, employees and agents), make any representation or warranty as to, or take any responsibility for, the accuracy, reliability, completeness or currency of any information or recommendations contained in this publication, nor its usefulness in achieving any purpose. ASA is not liable to users of this publication for any loss or damage however caused resulting from the use of this publication and accepts no responsibility for the accuracy of the information or your reliance on it. ASA does not endorse any product or service identified in this publication. ASA recommends users seek independent legal advice. ASA reserves all of its rights. See www.sonographers.org for the full ASA Publication disclaimer.