

THE SONOGRAPHER'S

QUICK REFERENCE GUIDE

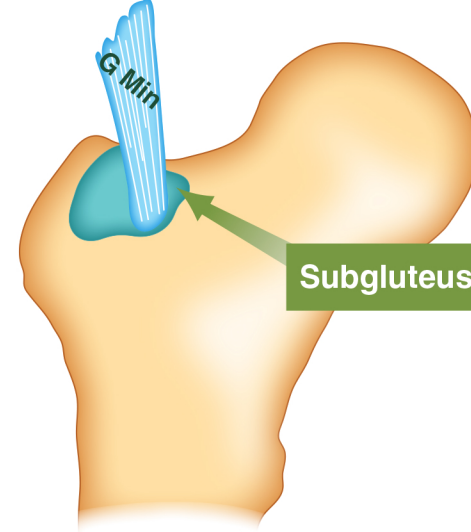
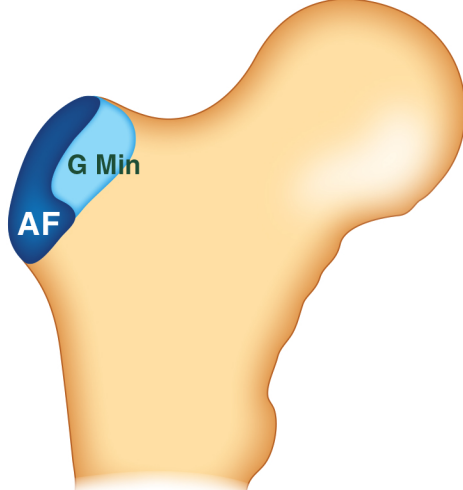
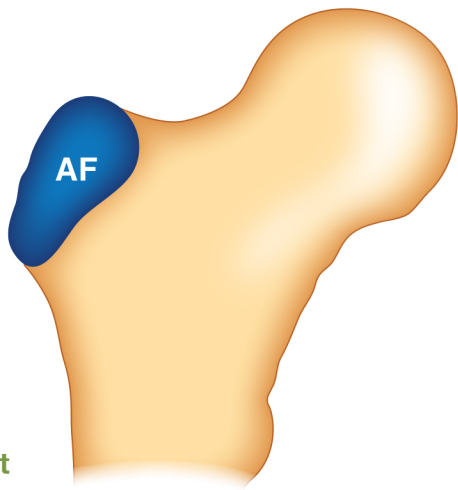
4 FACETS OF THE GREATER TROCHANTER

OSSEOUS ATTACHMENT SITES

BURSAE POSITIONS OF HIP

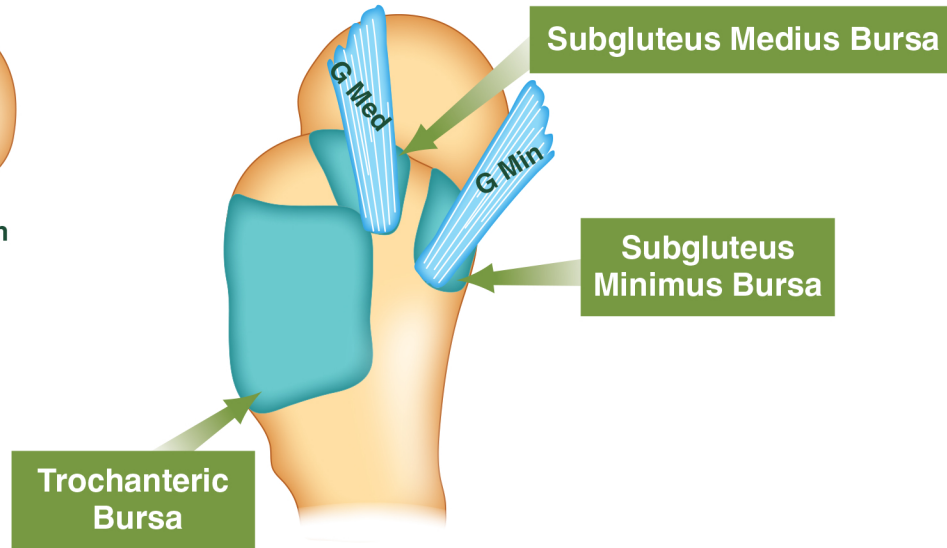
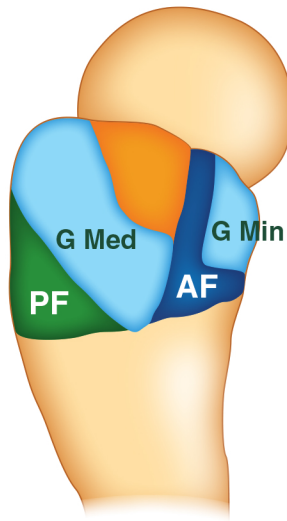
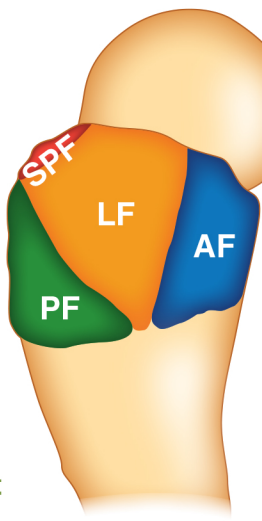
FRONTAL VIEW

AF = Anterior Facet



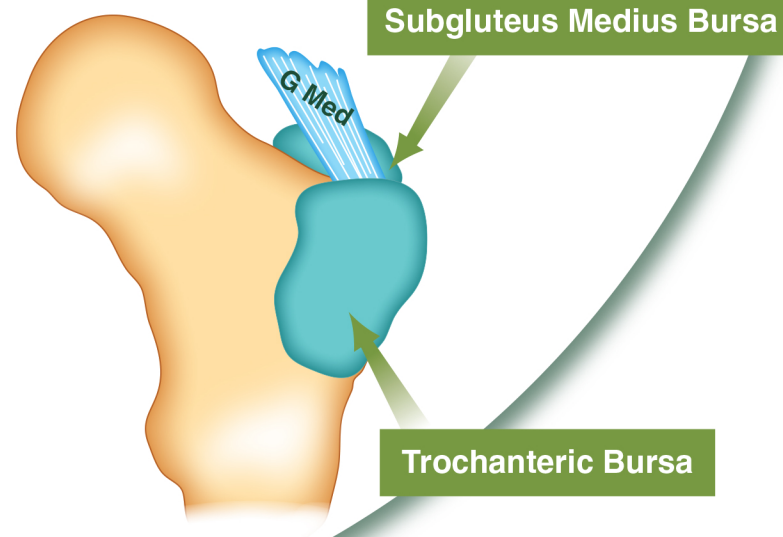
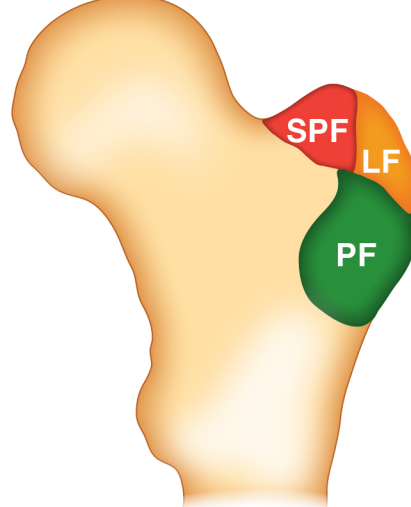
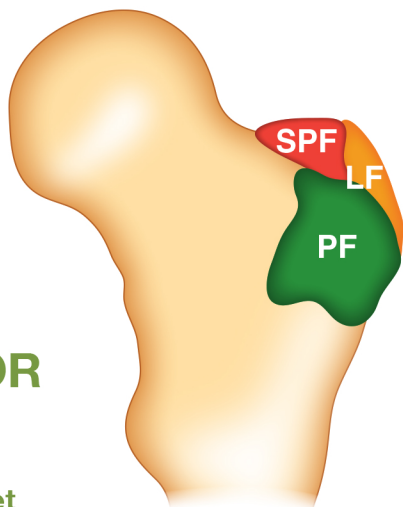
LATERAL VIEW

AF = Anterior Facet
LF = Lateral Facet
SPF = Superoposterior Facet
PF = Posterior Facet



POSTERIOR VIEW

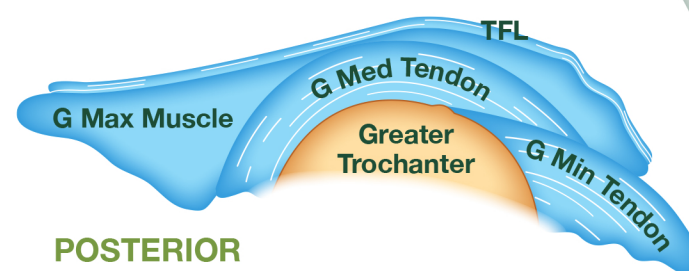
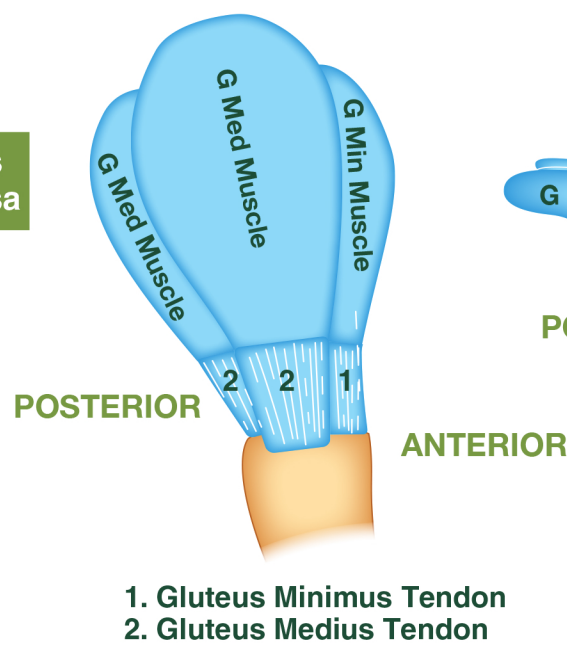
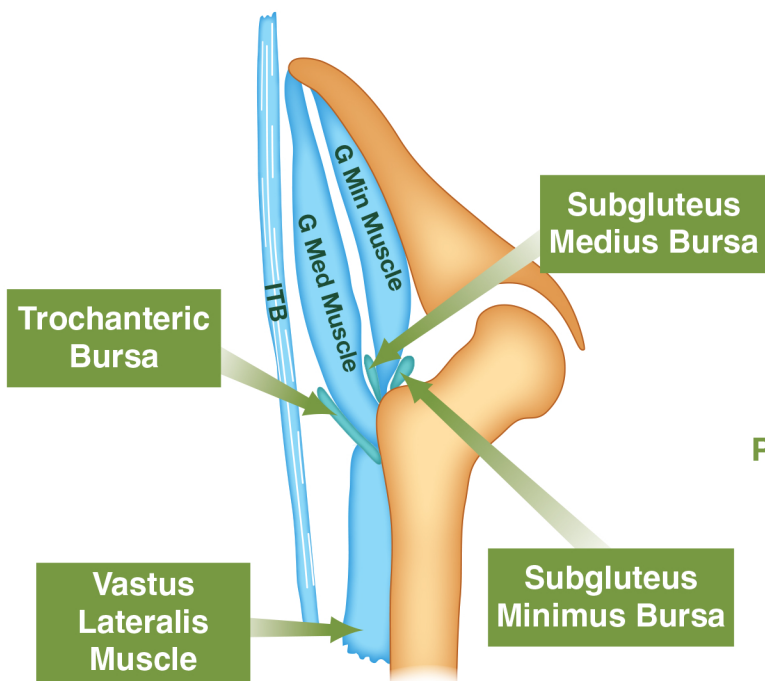
LF = Lateral Facet
SPF = Superoposterior Facet
PF = Posterior Facet



CORONAL VIEW

LATERAL VIEW

AXIAL VIEW



Anterior facet – located on the anterolateral surface of the trochanter. It corresponds to the insertion of the gluteus minimus tendon.

Lateral facet – has an inverted triangular shape (broader superiorly) and corresponds to the insertion of the gluteus medius tendon.

Superoposterior facet – forms the most cranial portion of the greater trochanter. It corresponds to the insertion of the superior portion of the gluteus medius tendon.

Posterior facet = bald spot of the greater trochanter. No tendinous insertion onto this facet covered by the the trochanteric bursa.

© 2010 Australasian Sonographers Association Ltd. This poster remains the property of the ASA. No part may be reproduced without permission. The Education Committee gratefully acknowledges Michelle Fenech for the preparation of this poster.

- References:
1. www.radsources.us – Stadnick M. Gluteus minimus tear and trochanteric bursitis. MRI web clinic. 2004 May.
 2. Civitanic O, Henzie G, Skezas N, Lyons J, Minter J. MRI diagnosis of tears of the hip abductor tendons (gluteus medius and gluteus minimus) American Journal of Roentology. 2004; (182):137-143.
 3. Pfirrmann C, Bhung C, Theumann N, Trudell D, Resnick D. Greater Trochanter of the hip: Attachment of the Abductor mechanism and a complex of three bursae – MR imaging and MR bursography in cadavers and MR imaging in asymptomatic volunteers. Radiology. 2001; (221):469-477.
 4. Beggs I, Bianchi S, Bueno A, Cohen M, Court-Payen M, Grainger A, Kalinberger F, Klausner A, Martinoli C, McNally E, O'Connor P, Peetrons P, Reijnierse M, Rempik P, Silvestri E. Musculoskeletal ultrasound technical guidelines: Hip. European society of musculoskeletal radiology. www.essr.org Anatomical variations may exist.

Disclaimer: © 2023 Australasian Sonographers Association Ltd. The Australasian Sonographers Association gratefully acknowledges the Sonographer Women's Health Special Interest Group committee for preparation of this poster. This poster remains the property of the Australasian Sonographers Association. No part of it may be reproduced without permission. Disclaimer: The information in this publication is current when published and is general in nature; it does not constitute professional advice. Any views expressed are those of the author and may not reflect ASA's views. ASA does not endorse any product or service identified in this publication. You use this information at your sole risk and ASA is not responsible for any errors or for any consequences arising from that use. Please visit www.sonographers.org for the full version of the Australasian Sonographers Association publication disclaimer.